



47th ANNUAL SCIENTIFIC MEETING

DELAWARE VALLEY VASCULAR SOCIETY

THE UNION LEAGUE OF PHILADELPHIA
PHILADELPHIA, PENNSYLVANIA

Thursday, May 8, 2025

ADMINISTRATIVE OFFICE

Delaware Valley Vascular Society
9400 W. Higgins Rd., Suite 315, Rosemont, IL 60018
Telephone: 312-334-2321 · Fax: 312-334-2320
Email: DVVS@vascularsociety.org · www.vascular.org/dvvs

DELAWARE VALLEY VASCULAR SOCIETY

2024-2025 EXECUTIVE COUNCIL

Faisal Aziz, MD, President
Danielle Pineda, MD, President-Elect
Evan Deutsch, MD, Secretary
Nadia Awad, MD, Treasurer
Hong Zheng, MD, Councilor-at-Large
Michael Nooromid, MD, Councilor-at-Large
Michael Qaqish, MD, Councilor-at-Large

Douglas A. Troutman, DO, Past President
Dawn M. Salvatore, MD, Past President

COMMITTEES

Membership

Laurel Hadley Hastings, MD, Chair

Program

Gregory Salzler, MD, Chair

Bylaws

Vincent DiGiovanni, MD, Chair

DELAWARE VALLEY VASCULAR SOCIETY

PAST PRESIDENTS

1979-1980.....	Charles C. Wolferth, Jr. MD
1980-1981.....	Charles C. Wolferth, Jr. MD
1981-1982.....	Robert Tyson, MD
1982-1983.....	Rudolph C. Camishion, MD
1983-1984.....	William Gee, MD
1984-1985.....	Paul Nemir, Jr. MD
1985-1986.....	Brooke Roberts, MD
1986-1987.....	Dominic A. DeLaurentis, MD
1987-1988.....	Gary G. Nicholas, MD
1988-1989.....	Arthur G. Baker, Jr. MD
1989-1990.....	Richard K. Spence, MD
1990-1991.....	Henry D. Berkowitz, MD
1991-1992.....	Anthony J. Comerota, MD
1992-1993.....	Brian L. Thiele, MD
1993-1994.....	William H. Hardesty, MD
1994-1995.....	R. Anthony Carabasi, MD
1995-1996.....	John V. White, MD
1996-1997.....	James B. Alexander, MD
1997-1998.....	Keith D Calligaro, MD
1998-1999.....	Robert G. Atnip, MD
1999-2000.....	Thomas K. Evans, MD
2000-2001.....	Mark B. Kahn, MD
2001-2002.....	Matthew J. Dougherty, MD
2002-2003.....	Eric C. Jaxheimer, MD
2003-2004.....	Michael A. Golden, MD
2004-2005.....	David P. Franklin, MD
2005-2006.....	Paul J. DiMuzio, MD
2006-2007.....	John Blebea, MD
2007-2009.....	Robert J. DiGiovanni, MD
2009-2010.....	John J. Flanagan, Jr. MD
2010-2011.....	Edward Y. Woo, MD
2011-2012.....	Frank Schmieder, MD
2012-2013.....	Ralph P. Ierardi, MD
2013-2014.....	James R. Elmore, MD
2014-2015.....	Joseph V. Lombardi, MD
2015-2016.....	Benjamin M. Jackson, MD
2016-2017.....	Theodore Sullivan, MD
2017-2018.....	Grace J. Wang, MD
2018-2019.....	Rashad Choudry, MD

2019-2020.....	Eric Choi, MD
2020-2021.....	Jose Trani, MD
2021-2022.....	Evan Ryer, MD
2022-2023.....	Dawn Salvatore, MD
2023-2024.....	Douglas Troutman, DO

The purpose of this meeting is to present state-of-the art clinical research and vascular biology relating to surgical aspects of vascular disease. The program will include presentations of original research by investigators in the field of Vascular Surgery and other areas of practice building. A significant portion of the program has been reserved for question-and-answer interaction between the presenters and the audience.

PROGRAM OBJECTIVES

At the end of this activity, participants will be able to:

1. Discuss long term results of iliac vein stenting procedures.
2. Discuss current management techniques for upper extremity venous disease, including dialysis related disease.
3. Discuss utilization of new technologies and devices in the treatment of venous disease
4. Discuss diagnosis and treatment of pelvic congestion syndrome

The Delaware Valley Vascular Society wishes to recognize and thank the following company(ies) for their monetary commercial support:

-Medtronic, Inc.

- W. L. Gore & Associates

BEST TRAINEE AWARD

Abstracts presented by our trainees will be eligible for the Clinical Research Award, Basic Science/Case Report Award, Medical Student Award and Poster Award.

DVVS members will conduct the review and scoring of these presentations. Please complete the score sheet and return them to the registration counter by 5:00 pm. There will be monetary awards and certificates presented to each winner at the evening's dinner.

Delaware Valley Vascular Society
47th Annual Meeting
Thursday, May 8, 2025
The Union League of Philadelphia

SCIENTIFIC PROGRAM

- 11:00 am **Welcome**
Faisal Aziz, MD, President, Delaware Valley Vascular Society
- 11:05 am - 12:10 pm **Rapid Fire Case Presentations**
- 11:05 - 11:12 am **Explantation to Salvage Unexpanded Carotid Stent**
Alexander German, MD, Laura Monaco, MD, Eric Shang, MD Benjamin Jackson, MD
Lehigh Valley Health Network
- 11:12 - 11:19 am **TEVAR for an Iatrogenic Penetrating Aortotomy in an Unstable Patient**
Ryan J. Bonner, BS, Dana J. McClosky, MD, John H. Cooper, DO, FACOS, RPVI
Atlanticare Regional Medical Center
- 11:19 - 11:26 am **Management of a Symptomatic Aortic Aneurysm with Off-Label Iliac Branched Endoprosthesis**
Theja Bhamidipati, DO, Constantine Troupes, MD, Ann Yufa, MD, Evan Deutsch, MD, Nadia Awad, MD
Einstein Medical Center
- 11:26 - 11:33 am **Case Report: Hybrid Management of Transplanted Renal Artery Pseudoaneurysm**
Ali Hakimi, MD, Jacob W. Soucy, MS, Faisal Aziz, MD, MBA, FACS
Penn State Health Milton S. Hershey Medical Center
- 11:33 - 11:40 am **Delayed Diagnosis of Primary Aortoenteric Fistula Requiring Open Surgical Reintervention**
Lena Chatterjee MD, Ann Yufa MD, Evan Deutsch, Nadia Awad, MD
Einstein Medical Center
- 11:40 - 11:47 am **Vasculitis Presenting with Atypical Symptoms and a Large Common Carotid Artery Aneurysm**
Raquel Vicario-Feliciano, MD, Andrew Shevitz, DO, Maria C. Castello-Ramirez, MD
Penn State Health Milton S. Hershey Medical Center

11:47 -11:54 am	<p>Open Repair of a Ruptured Mycotic Thoraco-Abdominal Aortic Aneurysm Secondary to Clostridium difficile Infection</p> <p>Abdul Wasay Paracha BS, Raquel Vicario Feliciano, MD, Tarik Ali, MD, Ahsan Zil-E-Ali, MBBS, MPH, Faisal Aziz, MD <i>Penn State Health Milton S. Hershey Medical Center</i></p>
11:54 am-12:01 pm	<p>Exsanguinating Hemorrhage from an Esophageal-Aberrant Right Subclavian Artery Fistula Treated with TEVAR</p> <p>Charles R. Vasquez, MD, M. Ibrahim, MD, Shang Loh, MD <i>University of Pennsylvania</i></p>
12:01 pm-12:08 pm	<p>Inferior Vena Cava Reconstruction with Cryopreserved Aortic Homograft for Prosthetic Graft Infection</p> <p>Arthur Holand, MD, Sherwin Mashkouri, MD, Sam Yellin, MD, Kundanika Lakkadi, MD, MS, Shivangi Bhatt, MD, Mila Ju, MD, Benjamin Jackson, MD <i>Lehigh Valley Health Network</i></p>
12:10 - 1:10 pm	Lunch & Exhibits
1:10 - 2:10 pm	<p>Complex Venous Disease Panel</p> <ul style="list-style-type: none"> • Rob Ford, MD: Long-term Iliac Stenting • Matthew Dougherty, MD: Venous Thoracic Outlet • Rob Meisner, MD: Newer Devices for Clot Removal • Marissa Famularo, MD: Pelvic Congestion Syndrome
2:10 - 2:30 pm	Coffee Break & Exhibits
2:30 - 4:35 pm	CLINICAL RESEARCH PRESENTATIONS
2:30 - 2:39 pm	<p>TEVAR with Dissection Stent for Malperfusion in Acute Type A Aortic Dissection: A Bridge to Open Repair</p> <p>Nicola Habash, BS, Avinash Saraiya, Cristina Micale, Alexander Zavitsanos, Babak Abai, MD, Dawn Salvatore, MD, Paul DiMuzio, MD, Michael Nooromid, MD <i>Thomas Jefferson University Hospital</i></p>
2:39 – 2:48 pm	<p>Clinical and Financial Impact of a Machine Learning Powered Screening Program for Abdominal Aortic Aneurysms</p>

Joseph Allen, MD, Alexander D. Pretko MS, MBA, Evan J. Ryer MD, MBA, James R. Elmore MD, Gregory G. Salzler MD, Emily Unrue DO, Anthony J. Lewis MD, David K. Vawdrey PhD, Rebecca M. Maff MS, Elliot G. Mitchell PhD
Geisinger Medical Center

2:48 - 2:57 pm

It's Not If You Get Sued, It's When: A Survey of Trends and Perceptions of Legal Involvement Amongst Vascular Surgeons

Yun Ke (Tracy) Du, MD, Matthew J. Dougherty, MD, Keith D. Calligaro, MD, Douglas A. Troutman, DO
Pennsylvania Hospital (UPHS)

2:57 - 3:06 pm

Safety and Efficacy of Bivalirudin as a Heparin-Alternative in Patients Undergoing Carotid Artery Stenting

Alexandra L. Maningat, DO, Thomas A. Kania MD, Sahaj S. Shah BS, Tian Guo MS, , James R. Elmore MD, Evan J. Ryer MD, Gregory S. Salzler MD
Geisinger Medical Center

3:06 - 3:15 pm

Characterizing the Demographic Composition of Editorial Board Members of High-Ranking Vascular Surgery Journals

Conor Dougherty, BS, Saaniya Farhan, BS, Cristina Micale, BS, Matthew Ruiz, BA, BS, Alya Wilkinson-Hayat, BS, Adam Ostrovsky, BS, Michael Nooromid, MD, Babak Abai, MD
Thomas Jefferson University

3:15 - 3:24 pm

Endovascular Intervention for Iatrogenic Popliteal Artery Injury Following Total Knee Arthroplasty

Tyler Fox, MD, Ioannis Tsouknidas, MD, Alvaro Mendez, MD, Alexandra Kats, MS, Henry Hirsch, MD, Robert Meisner, MD, Daniel Hayes, MD, Gerald Patton, MD, Alexander Uribe, MD, Vincent DiGiovanni, DO
Lankenau Medical Center

3:24 – 3:33 pm

The Effect of Preoperative Ejection Fraction on Ambulation after Major Amputation

Chris DeHaven MD, Patrick D Conroy MD, Beshar Tolaymat MD, Matthew Bye MD, Katherine McMackin MD, Laurel H. Hastings MD, Bruce L Tjaden Jr. MD
Cooper University Hospital

3:33 – 3:42 pm

Preoperative History of Gabapentinoids Use is Associated with Longer Length of Hospital Stay in Patients Undergoing Lower Extremity Bypass Surgery for Severe Peripheral Arterial Disease

Fadi Samaan, BS, Elizabeth Lavanga, BS, Leana Dogbe, BS, Ahsan Zil-E-Ali, MBBS, MPH, Faisal Aziz, MD, MBA, FACS, DFSVS

Penn State Health Milton S. Hershey Medical Center

3:42 – 3:51 pm

The Paradox of Early Surgery and Worse Outcomes in Ruptured Abdominal Aortic Aneurysms

Ahsan Zil-E-Ali, MBBS, MPH, Aditya Safaya, MD, Esther S. Choi, MD, Kristine So, MD, Faisal Aziz, MD

Penn State Health Milton S. Hershey Medical Center

3:51 – 4:00 pm

Female Sexual Dysfunction After EVAR

Alec Schubert MD, Bruce L Tjaden Jr MD, Patrick D. Conroy MD, Olivia M. Toner BS, Holly A. Seybold BA, Alison M. Blumstein BS, Benjamin Feng, BS, Philip Batista MD, Laurel H. Hastings MD, Joseph V. Lombardi MD, MBA, Katherine McMackin MD

Cooper University Hospital

4:00 – 4:09 pm

Clinical Outcomes of Femoral Endarterectomy using Monitored Anesthesia Care

Brian N. Lifschutz, DO, Osama Anis, MD, James Zamora, MD, Hudson Carter, MD, Robert Myers, MD, Jaclyn Milici, MD, and Danielle M. Pineda, MD

Jefferson-Abington Hospital

4:09 – 4:18 pm

Smaller and More Rural Hospitals have Worse Outcomes in Aortic Dissection Management

Patrick D. Conroy MD, Bruce Tjaden MD, Beshar Tolaymat MD, Alec Schubert MD, Laurel Hastings MD, Katherine McMackin MD, Philip Batista MD, Joseph V Lombardi MD

Cooper University Hospital

4:18 – 4:27 pm

Novel Morphological Predictors of Stroke Risk in Carotid Artery Stenosis: A Comparative Analysis of Plaque Characteristics Beyond Luminal Narrowing

Danielle C. Brown, BS, Patrick D. Conroy MD, Bruce L Tjaden Jr MD, Katherine McMackin MD, Laurel H. Hastings MD, Philip M Batista MD, Joseph L. Lombardi MD MBA

Cooper University Hospital

4:27 – 4:36 pm

Transcarotid Artery Revascularization is Safe and Durable in Patients with Hostile Neck Anatomy

Ryan Lee, BS, Michael Qaqish, MD, Sharvil Sheth, MD

St. Luke's University

4:40 – 4:50 pm

DVVS Member Business Meeting

4:50 - 5:00 pm

Past President Recognition & Toast

5:00 - 5:30 pm

Reception & Exhibits

5:30 - 7:00 pm

Dinner and Keynote Lecture

Complex Venous Work

Claudie Sheahan, MD

Professor of Clinical Surgery

Louisiana State University, New Orleans

POSTERS

- 1. Patients undergoing axillobifemoral bypass to the profunda femoris artery have increased risk of major amputation**
Raquel Vicario-Feliciano, MD, Ahsan Zil-E-Ali, MBBS, MPH, Faisal Aziz, MD, FACS, RPVI, MBA, DFSVS
Penn State Health Milton S. Hershey Medical Center
- 2. Single-Center Experience Using Endologix AFX Device for Treatment of Aortoiliac Occlusive Disease**
Isabella H. Muti, BA, Gaurang Joshi, MD, Dawn M. Salvatore, MD, Michael J. Nooromid, MD, Paul J. DiMuzio, MD, Babak Abai, MD
Thomas Jefferson University Hospital
- 3. Case Report: Conservative Management of Middle Aortic Syndrome**
Ali Hakimi, MD, Faisal Aziz, MD, MBA, FACS
Penn State Health Milton S. Hershey Medical Center
- 4. Revascularization Intervention History is Associated with Reduced Mortality in Chronic Limb-Threatening Ischemia Patients Undergoing Major Amputation**
Tarik Ali, MD, Fadi Samaan, BS, Jacob W. Soucy, MS, Elizabeth Lavanga, BS, Esraa A. Abu Tair DDS, Faisal Aziz MD, FACS, DFSVS
Penn State Health Milton S. Hershey Medical Center
- 5. Frailty and Anatomical Complexity Drive Mortality in Patients Unfit for Open AAA Repair**
Ahsan Zil-E-Ali, MBBS, MPH, Aditya Safaya, MD, Faisal Aziz, MD
Penn State Health Milton S. Hershey Medical Center
- 6. Modern endografts can provide a surgical alternative to high-risk patients with infrarenal abdominal aortic aneurysms**
Raquel Vicario-Feliciano, MD, Andrew Shevitz, DO, Maria C. Castello-Ramirez, MD
Penn State Health Milton S. Hershey Medical Center
- 7. Carotid-to-Brachial Artery Bypass for Traumatic Axillary Artery Injury**
Alec J. Schubert MD, Bruce L. Tjaden MD, Patrick D. Conroy MD
Cooper University Hospital
- 8. Meta-Analysis Investigating the Association Between Pre-Existing**
Ahsan Zil-E-Ali MBBS MPH, Abdul Wasay Paracha BS, Esther S. Choi BA, PhD, Ahmad Abdeen BS, Faisal Aziz MD MBA FACS DFSVS
Penn State Health Milton S. Hershey Medical Center

9. Predictors of Extended Length of Stay following Transcarotid Artery Revascularization (TCAR)

Arjun Kumar, BS, Patrick D Conroy, MD, Shivani Raizada, BA, Alec Schubert, MD, Mikael Fadoul, MD, Bruce L Tjaden Jr MD, Katherine McMackin MD, Laurel H. Hastings MD Joseph V. Lombardi, MD, MBA, Philip M. Batista, MD
Cooper University Hospital

10. Patency of Major Abdominal Vessel Reconstructions When Assisting in Whipple Procedures

Javier Eraña MD, Patrick D. Conroy MD, Sachin Mysore BS, Aakanksha Gupta MD, Johanna Lou MD, Bruce Tjaden MD, Laurel Hastings MD, Young Ki Hong MD MPH, Francis R Spitz MD, Katherine McMackin MD
Cooper University Hospital

11. Endovascular Management of Superior Mesenteric Artery Dissection

Andrea McSweeney, MD, Mohammad Irfan Ali, MD, Dawn Salvatore, MD, Paul Dimuzio, MD, Michael Nooromid, MD, Babak Abai, MD
Thomas Jefferson University Hospital

12. Technique of Baroreflex Activation Therapy Device Implantation

Aakanksha Gupta, MD, Patrick Conroy, MD, Katherine McMackin, MD, Laurel H. Hastings, MD, Philip Batista, MD and Joseph V. Lombardi, MD, MBA
Cooper University Hospital

ABSTRACTS

11:05 - 11:12 am

Explantation to Salvage Unexpanded Carotid Stent

Alexander German, MD, Laura Monaco, MD, Eric Shang, MD Benjamin Jackson, MD
Lehigh Valley Health Network

Introduction

Carotid angioplasty and stenting are sometimes performed emergently, such as during percutaneous thrombectomy for embolic strokes. However, some neurointerventionalists may not fully recognize the anatomic features that render carotid stenting relatively contraindicated. Notably, circumferential calcification can lead to in-stent stenosis and an increased risk of stroke recurrence. Residual stenosis after carotid stenting is associated with long-term restenosis and the potential need for reintervention.

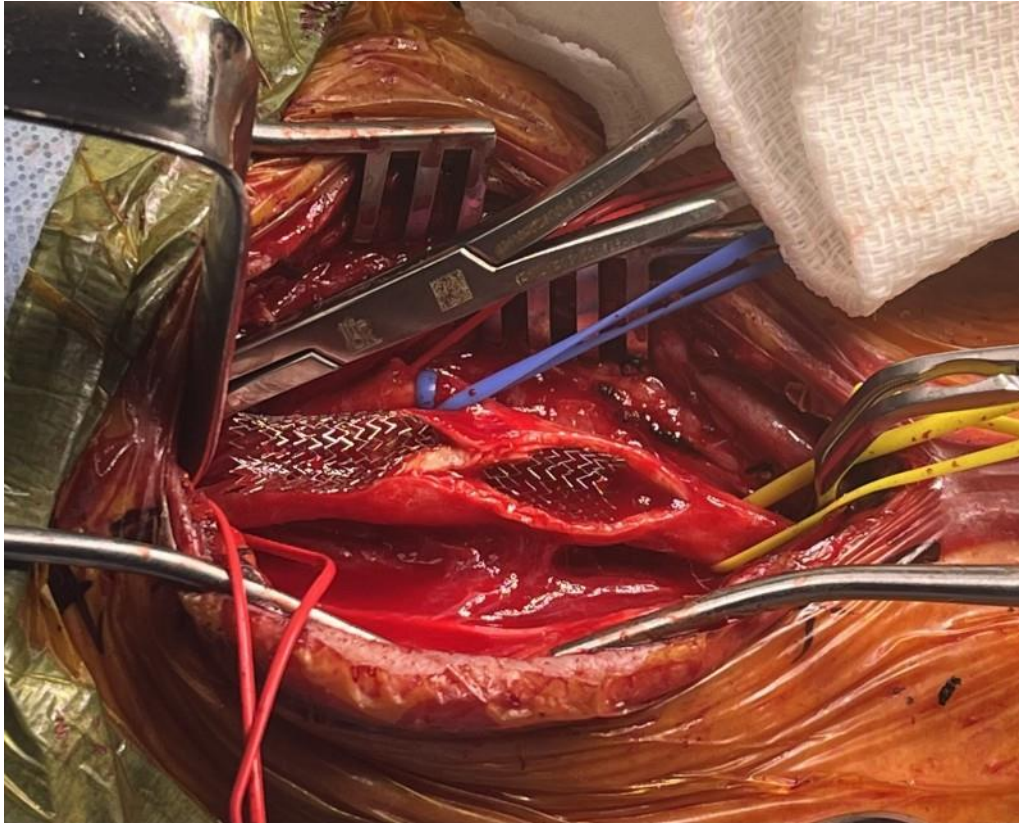
Case Description

A 68-year-old male presented with left-sided weakness, facial weakness, slurred speech, and an NIH Stroke Scale score of 11. Imaging revealed complete occlusion of the right internal carotid artery and the M1 and M2 segments. The patient was treated with Tenecteplase and underwent angiography, thrombectomy, and stenting of the right internal carotid artery. Despite post-dilation, significant stent recoil was observed. Postoperative carotid duplex ultrasound (CDUS) suggested possible stenosis, which a CT angiogram confirmed as dense circumferential calcific plaque with significant in-stent stenosis. The stent lumen measured 1 mm, indicating 80% stenosis. Following an interdisciplinary discussion with neurology, neurointerventional radiology, vascular surgery, and the patient, it was decided to proceed with stent explantation, endarterectomy, and bovine pericardial patch angioplasty. The stent was found trapped within calcified plaque and was explanted without difficulty. The patient experienced no postoperative neurological deficits, and a surveillance CDUS one month later showed a patent endarterectomy site with no evidence of stenosis.

Discussion/Conclusion

This case underscores the critical importance of assessing lesion characteristics in preoperative planning. The concentric calcified plaque in this patient hindered adequate stent expansion, leading to significant in-stent stenosis. Prompt stent removal and definitive endarterectomy were essential for successful management, highlighting the need to evaluate anatomic features that may impact carotid stenting outcomes.

Intraoperative photograph of stent compression by plaque prior to delivery of the stent



11:12 - 11:19 am

TEVAR for an Iatrogenic Penetrating Aortotomy in an Unstable Patient

Ryan J. Bonner, BS, Dana J. McClosky, MD, John H. Cooper, DO, FACOS, RPVI

Atlanticare Regional Medical Center

Objectives

We present a case of a 52 y.o. female who presents with an iatrogenic aortic puncture from a supraclavicular cordis sheath insertion. She was transferred to our institution from an outside hospital with a history of vaginal bleeding and hemodynamic collapse requiring VA ECMO. In the ICU, patient underwent placement of a 9 French cordis sheath. However, the catheter inadvertently punctured the aortic arch 5mm distal to the L-CCA. The patient was not deemed a candidate for an open aortic arch repair and instead, a TEVAR was chosen to repair the defect.

Methods

The patient was brought to the operating room for TEVAR. During the TEVAR deployment, the graft successfully excluded the aortotomy but partially covered the ostia of the left common carotid artery. A wire was passed through the femoral artery in an attempt to gain antegrade access to the left common carotid artery which was unsuccessful. The decision was made to make a cutdown on the left common carotid and gain retrograde access to place a 6x29mm VBX covered stent. The graft was deployed and there was antegrade flow from the left common carotid artery and there was retrograde flow from the vertebral artery.

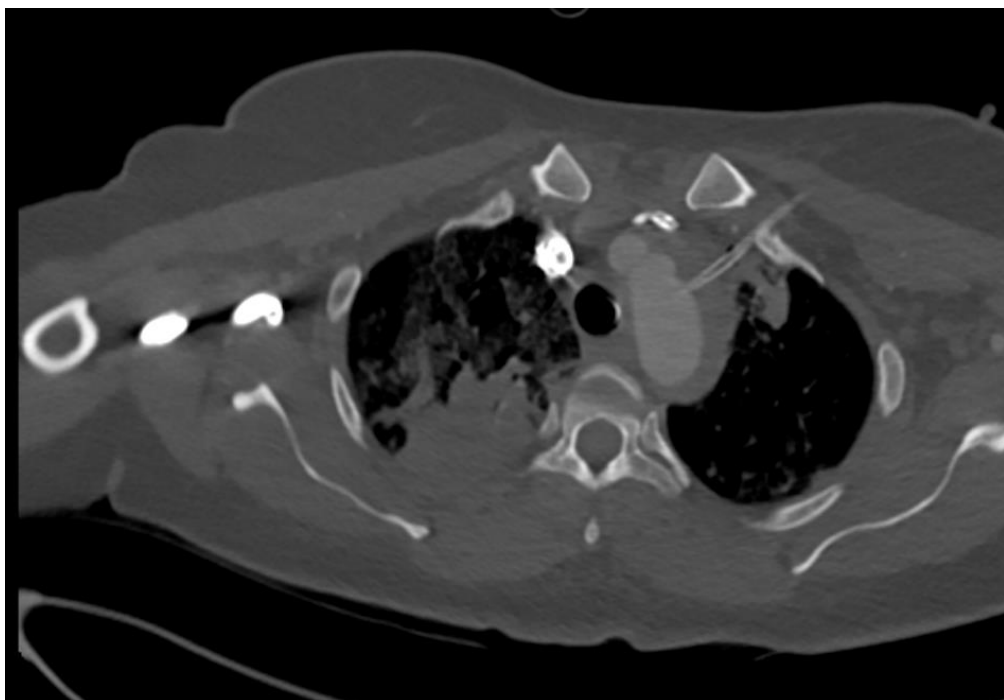
Results:

The patient was returned to the CVICU in critical but stable condition.

Conclusion:

Aortic puncture is a dreaded complication of cordis sheath cannulation. TEVAR offers an alternative to open arch repair but also may present complications in balancing exclusion of a site of injury and maintaining patency of branch vessels. This case highlights the surgical team's adaptability when deploying endografts in complex, critically ill patients.

Figure 1: CT scan of chest demonstrating cordis catheter placement into the lumen of the zone 2 aortic arch.



Management of a Symptomatic Aortic Aneurysm with Off-Label Iliac Branched Endoprosthesis

Theja Bhamidipati, DO, Constantine Troupes, MD, Ann Yufa, MD, Evan Deutsch, MD, Nadia Awad, MD
Einstein Medical Center

Introduction

Off the shelf aortic stent grafts offer a quick and reliable method for intervening in urgent and emergent settings. However these grafts are limited by their anatomic feasibility, in particular their length and diameter. This case outlines a novel use of an off-label endovascular stent graft in an emergent setting due to anatomic constraints.

Case

The patient is a 77 year old female with a history of coronary artery disease, tobacco abuse, asthma, COPD, previous bilateral kissing iliac stents, and a known 4.5cm infrarenal abdominal aortic aneurysm (AAA) which was last measured approximately 9 months earlier. The patient presented to an outside hospital with complaints of back pain and pulsatility within her abdomen. Due to concern of a symptomatic AAA, the patient was scanned which subsequently showed an interval increase of the aneurysm sac to 5.2cm. Patient was urgently transferred with plans to go to the operating room for endovascular repair over open surgery. The patient's CTA was reviewed showing patent common iliac stents. The length from the lowest renal artery to the proximal extent of the iliac stent measured approximately 60cm. The proximal aortic neck diameter was 18mm. Due to these anatomic constraints, off the shelf aortic stent grafts were unable to be deployed since the contralateral gate would not be able to be opened with the previously placed iliac stent. Thus, the decision was made to use a GORE EXCLUDER Iliac Branched Endoprosthesis as an aortic stent graft. A 23mm x10cm Main body, 12mm x 10cm Left limb, and a 12mm x 7cm Right limb were deployed and ballooned. Completion angiogram showed appropriate exclusion of the aneurysm without any type 1 or 3 endoleaks. She recovered well postoperatively. At follow up there was interval decrease in her aneurysm sac and resolution of her pain.

Conclusion

In an emergent setting, off the shelf devices may not be feasible. Innovative use of available grafts and off-label use may be needed to appropriately intervene in patients who are not open surgical candidates.

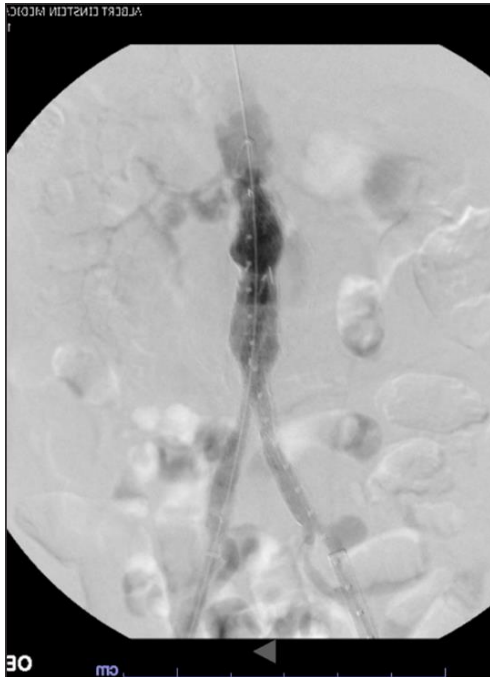


Fig 1. Completion angiogram of IBE placed within aorto-iliac system

11:26 - 11:33 am

Case Report: Hybrid Management of Transplanted Renal Artery Pseudoaneurysm

Ali Hakimi, MD, Jacob W. Soucy, MS, Faisal Aziz, MD, MBA, FACS

Penn State Health Milton S. Hershey Medical Center

Background: Pseudoaneurysm formation following renal transplantation is a rare but serious complication¹. While the standard for managing such complications has traditionally been open surgical repair, endovascular techniques are increasingly considered to preserve graft function².

Methods: We present the case of a 54-year-old male with a history of a failed right kidney and pancreas transplant, now status post left kidney transplant. He presented with left-sided abdominal pain and leg numbness, leading to the discovery of a pseudoaneurysm in the left external iliac artery near the transplanted renal artery. Following several unsuccessful attempts at percutaneous coiling of the pseudoaneurysm, recurrent symptoms, and unsuitable open surgical anatomy with risk for allograft loss, a hybrid surgical repair was indicated.

Results: The patient underwent successful placement of a 6x39mm VBX covered stent with a 9x38mm iCAST stent extension from the transplanted renal artery into the distal left external iliac artery, followed by coil embolization of the proximal external iliac artery (Figure 1). To ensure adequate blood flow to the left leg, a femorofemoral bypass was performed using an 8mm rifampin-soaked ringed PTFE graft. The patient's post-operative course was complicated by a groin lymph leak, requiring wound vacuum-assisted closure (VAC) placement. He was discharged on post-operative day 14 with prescriptions for clopidogrel, rivaroxaban, and long-term suppressive antibiotics. Over a follow-up period of six years, the patient has remained asymptomatic with maintained renal allograft function.

Discussion: This report underscores the complexities in managing pseudoaneurysms in renal transplant patients, particularly when anatomical challenges and the risk of graft loss complicate standard treatment. It highlights the potential of a hybrid surgical-endovascular approach in preserving allograft function and long-term stability. This case supports the growing role for endovascular techniques in the management of transplant-related vascular complications^{2,3}.

References:

1. Anders L, Stephens R, Laub M, Amarath-Madav R, Mirza A, Saeed MI. Management of Transplant Renal Artery Pseudoaneurysm and Literature Review. *Case Reports in Transplantation*. 2022;2022:1-10.
2. Sharma N, Bidnur S, Caldas M, McNally D, Murray A, Turnbull R, et al. Renal transplant anastomotic pseudoaneurysms: Case report of open repair and endovascular management. *IJU Case Reports*. 2019;2(2):86-9.
3. Buimer MG, Van Hamersvelt HW, Adam Van Der Vliet J. Anastomotic pseudoaneurysm after renal transplantation; a new hybrid approach with graft salvage. *Transplant International*. 2012;25(7):e86-e8.

62 year-old incarcerated male with a past medical history of tobacco use and hypertension was evaluated outpatient for an enlarging, asymptomatic 5.5cm infrarenal abdominal aortic aneurysm. While undergoing work up for elective repair, the patient presented with acute onset back pain and labs significant for hemoglobin 3.4. CTA demonstrated a partially thrombosed aneurysm now measuring 7.2cm. Given his symptomatic AAA with concern for impending rupture, the patient underwent an emergent endovascular repair with a bifurcated aortic endograft. Subsequent anemia work up including labs and stool tests were negative.

Post-operative CTA surveillance imaging revealed air around the endograft and small bowel wall thickening. The patient was advised to return to the hospital, where he was found to be asymptomatic and stable. A white blood cell scan correlated with CTA findings. Given the concern for graft infection with possible aortoenteric fistula, open surgical intervention was pursued.

The patient underwent an exploratory laparotomy. A segment of bowel was found to be adherent to the aneurysm wall with obvious communication into the aneurysm sac. The area of affected small bowel was resected and anastomosed primarily. The aneurysm sac was resected, the endograft was removed, and a rifampin-soaked bifurcated Dacron graft was implanted. Vancomycin antibiotic beads were placed prior to closure. Intraoperative cultures were positive for E. Coli. He recovered well and was discharged on Augmentin indefinitely.

Rapid expansion of AAA may herald an infectious process. We believe this case represents a delayed diagnosis of primary aortoenteric fistula. The initial presentation thought to be an impending rupture likely represented a progression of fistulaization, with the endograft serving a temporizing measure. The explantation of the endograft and placement of antibiotic-soaked graft along with long term antibiotic coverage will serve as definitive treatment.

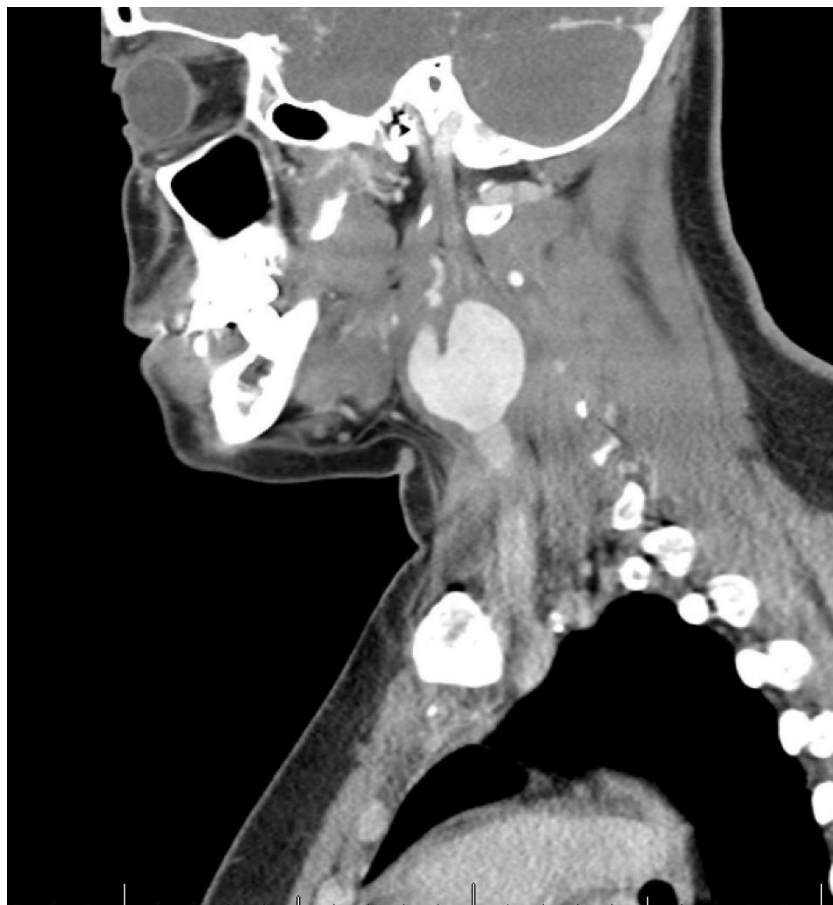Introduction: Carotid artery aneurysms are rare but they can carry a high degree of morbidity and mortality. Understanding the etiology of the aneurysm is essential to guide treatment.

Case Presentation: 19-year-old female presenting to the emergency department (ED) with sore throat, dysphagia and hoarseness. She had history of left neck pain for 2 months prior and intermittent episodes of jaw pain. She was evaluated by ENT that morning and asked to come for further evaluation after they noticed left vocal cord paralysis and a “large pulsatile mass” on endoscopy. CT angiography (CTA) of the neck was remarkable for a 3 cm aneurysm of the left distal common carotid artery (CCA) with intramural thrombus and possible occlusion of the proximal left internal carotid artery (ICA) (Figure A). Interestingly, patient was also noted to have a bovine arch on CTA. Patient denied any symptoms of transient ischemic attack (TIA) or stroke. She denied history of headache, neck trauma, intravenous drug use, and any recent head and neck infections. She also denied hypertension, fever, arthralgias, and claudication. She had a leukocytosis of 10.5. Her C-reactive protein was elevated to 11.3 and erythrocyte sedimentation rate was greater than 130. A thorough rheumatologic and infectious workup was performed. She was started on intravenous hydrocortisone and on day 4 had a TIA with a brief episode of aphasia. Repeat CTA showed extensive thrombus of the left ICA into the cavernous segment. She was started on therapeutic anticoagulation. Patient remained neurologically intact and on hospital day 6 was taken to the operating room. Intraoperative dissection of the aneurysm was challenging given extensive inflammation between the aneurysm and the surrounding tissue, particularly the vagus nerve. The vagus nerve did not stimulate with probe, consistent with known vocal cord paralysis. After 50 minutes of carotid clamp time with no changes on neuromonitoring, we elected to ligate the vessels with no revascularization pursued. Pathology was consistent with differential of Takayasu’s versus Giant Cell Arteritis.

Conclusion: Vasculitides do not always present with headache, claudication, blood pressure differential between extremities or a bruit. The presence of a carotid aneurysm in an otherwise healthy

patient with no risk factors should raise suspicion of vasculitis. These patients are best treated with steroids and/or immunomodulators during the inflammatory phase. However, young patients with significant carotid thrombus are at risk of stroke and may require earlier surgical intervention.

Figure A:



11:47 -11:54 am

Open Repair of a Ruptured Mycotic Thoraco-Abdominal Aortic Aneurysm Secondary to Clostridium difficile Infection
Abdul Wasay Paracha BS, Raquel Vicario Feliciano, MD, Tarik Ali, MD, Ahsan Zil-E-Ali, MBBS, MPH, Faisal Aziz, MD
Penn State Health Milton S. Hershey Medical Center

Background: Mycotic aneurysms are a rare but severe complication of infectious processes that involve the aorta and often require emergent surgical intervention. This case report discusses the presentation and management of a ruptured mycotic thoracoabdominal aortic aneurysm secondary to *Clostridium difficile* infection.

Case Presentation: A 62-year-old female with a history of hypertension, alcoholic cirrhosis, hypothyroidism, COPD, depression, substance use disorder (including prior intravenous drug use), and a known thoracoabdominal aortic aneurysm with aortitis presented as an emergent transfer for acute back and bilateral flank pain. A diagnostic CT angiogram of the chest, abdomen, and pelvis revealed findings concerning for a contained aortic rupture, emphysematous aortitis, and aspiration pneumonia in the right lower lobe, with a 3D reconstruction of the findings shown in **Figure 1**. The patient underwent emergent open aneurysm repair with a rifampin-soaked Dacron graft. During the procedure, the presence of purulent material in the retroperitoneal space and gross aortic rupture was noted. Cultures from periaortic swabs and aortic wall tissue were performed and confirmed the presence of *Clostridium difficile*. The positive culture swabs indicated infectious aortitis secondary to *Clostridium difficile* as the etiology of the mycotic aneurysm. Reconstruction of the aorta involved graft placement, reimplantation of mesenteric vessels and renal arteries, and bilateral iliac artery thrombectomy. Post-operatively, the patient developed abdominal compartment syndrome and hemoperitoneum, requiring exploratory laparotomy with a temporary abdominal wall closure. Two days later, the patient underwent an abdominal washout and closure, however, due to splenic congestion, a subsequent splenectomy was performed. Given the confirmed *Clostridium difficile* infection, the patient was initiated on a six-week course of intravenous antibiotics to reduce the risk of recurrent infection.

Conclusion: This rare case illustrates the significance of early recognition and treatment of ruptured mycotic thoracoabdominal aortic aneurysm while highlighting the importance of considering rare pathogens, such as *Clostridium difficile*, as the potential cause.

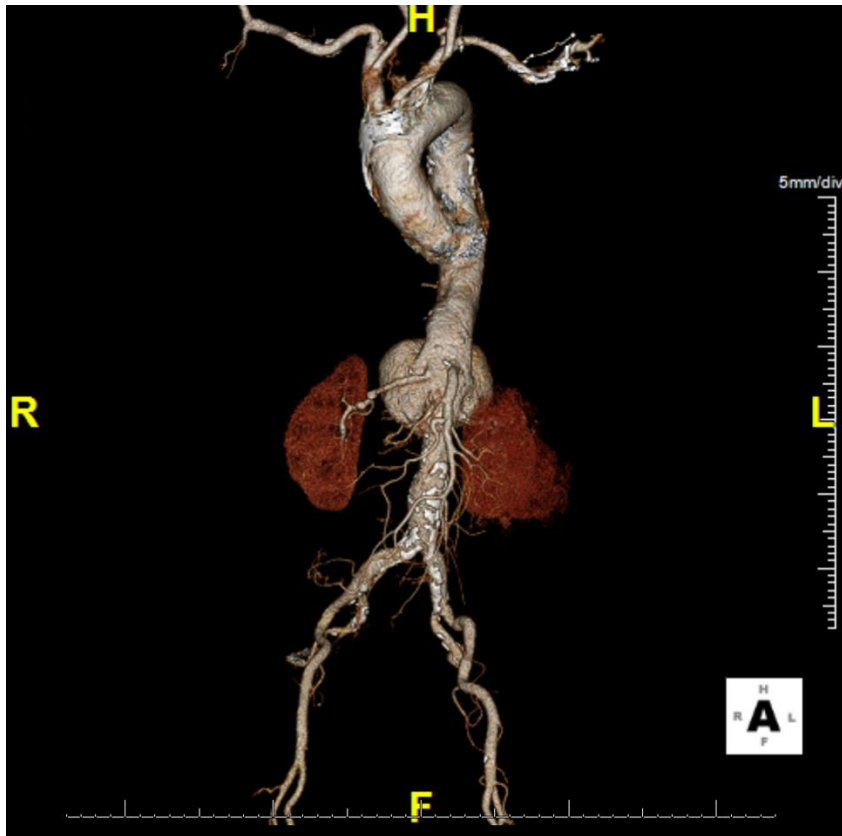


Figure 1. 3D reconstruction of the thoracoabdominal mycotic aneurysm.

15. Exsanguinating Hemorrhage from an Esophageal-Aberrant Right Subclavian Artery

Fistula Treated with TEVAR

Vasquez CR¹, Ibrahim M², Loh S¹

¹Division of Vascular and Endovascular Therapy, Department of Surgery, University of Pennsylvania

Perelman School of Medicine

²Division of Cardiovascular Surgery, Department of Surgery, University of Pennsylvania

Exsanguinating Hemorrhage from an Esophageal-Aberrant Right Subclavian Artery Fistula Treated with TEVAR**Charles R. Vasquez, MD**, M. Ibrahim, MD, Shang Loh, MD
University of Pennsylvania

A 59 year-old female with a history of type 2 diabetes, hypertension, chronic obstructive pulmonary disease (COPD), non-ischemic cardiomyopathy, chronic heart failure with reduced ejection fraction (HFrEF) on home milrinone therapy presented with decompensated heart failure and underwent Impella 5.5 implantation followed by Heartmate 3 LVAD placement seven days later. Her initial post-operative course was complicated by delayed sternal closure and respiratory failure requiring tracheostomy on post-operative day (POD) 12. On POD 32 the patient developed large volume hematemesis. Direct laryngoscopy, bronchoscopy and direct examination excluded the upper and lower airway as a bleeding source. Upper endoscopy showed extensive blood within the esophagus. Bleeding ceased after placement of an esophageal occlusion balloon. The patient underwent a CT angiogram which demonstrated an aberrant right subclavian artery (RSCA) and high-suspicion for an esophageal-subclavian artery fistula.

Given continued exsanguination when the esophageal occlusion balloon was deflated, the patient was taken emergently to the operating room. An aortogram was performed which did not show active bleeding while the esophageal balloon was inflated. With balloon deflation, the patient began rapidly bleeding, precluding the ability to perform an angiogram. A Cook Alpha 34mm x 113mm stent graft was deployed to cover the origin of the aberrant RSCA, resulting in reduction, but not complete cessation, of esophageal bleeding. The right brachial artery was accessed and catheter access into the RSCA obtained. The RSCA appeared occluded but given the patient's continued bleeding, we proceeded to pass a wire for coil embolization. In the aberrant RSCA, an angiogram confirmed contrast extravasation into the esophagus. We then deployed Penumbra Ruby coils from the Kommerell's diverticulum at the origin of the right subclavian artery up to the origin of the right vertebral artery with cessation of bleeding. Her post-operative course has been complicated by recurrent bacteremia requiring suppressive antibiotics, but no recurrent bleeding.

Inferior Vena Cava Reconstruction with Cryopreserved Aortic Homograft for Prosthetic Graft Infection

Arthur Holand, MD, Sherwin Mashkouri, MD, Sam Yellin, MD, Kundanika Lakkadi, MD, MS, Shivangi Bhatt, MD, Mila Ju, MD, Benjamin Jackson, MD
Lehigh Valley Health Network

Introduction

Inferior vena cava (IVC) reconstruction is uncommon in oncologic resections, and rarely necessary otherwise. We present a case of emphysematous pyelonephritis (EP) necessitating emergent right nephrectomy, complicated by inadvertent IVC ligation and resection. Initial reconstruction with a prosthetic graft failed due to infection, requiring subsequent IVC replacement with a cadaveric cryopreserved aortic homograft (CAH).

Case Description

A 31-year-old male with a history of diabetes mellitus presented in septic shock from EP. He underwent a right nephrectomy with inadvertent IVC ligation during right renal vein stapling. The IVC segment was replaced with an interposition Dacron graft and the left renal vein (LRV) was re-implanted.

On postoperative day 27, he developed sepsis from a graft infection, confirmed by CT showing a gas-filled fluid collection in the right renal fossa. He underwent percutaneous drainage and antibiotics. A venogram showed IVC and LRV patency. On day 60, the infected Dacron graft was replaced with a cadaveric aortic homograft (CAH) with LRV reimplantation (Figure 1). Post-operative recovery included non-operative chyle leak management and 21-day course of IV antibiotics, with no persistent infection noted.

Discussion

While caval (and concomitant left renal vein ligation) were considered, the risk of lower extremity phlegmasia, limb loss, or left kidney failure requiring dialysis led us to prioritize IVC and LRV reconstruction during the initial operation. Before reoperation, a venogram confirmed the IVC and LRV patency, guiding our decision to replace the infected graft with a CAH. If occlusion had been detected, graft excision without reconstruction would have been feasible.

This case appears to be the first report of IVC reconstruction after prosthetic graft infection.

There is limited documentation in the literature on this reconstruction technique.

Conclusion

CAH represents an attractive conduit for vena cava replacement in contaminated fields.

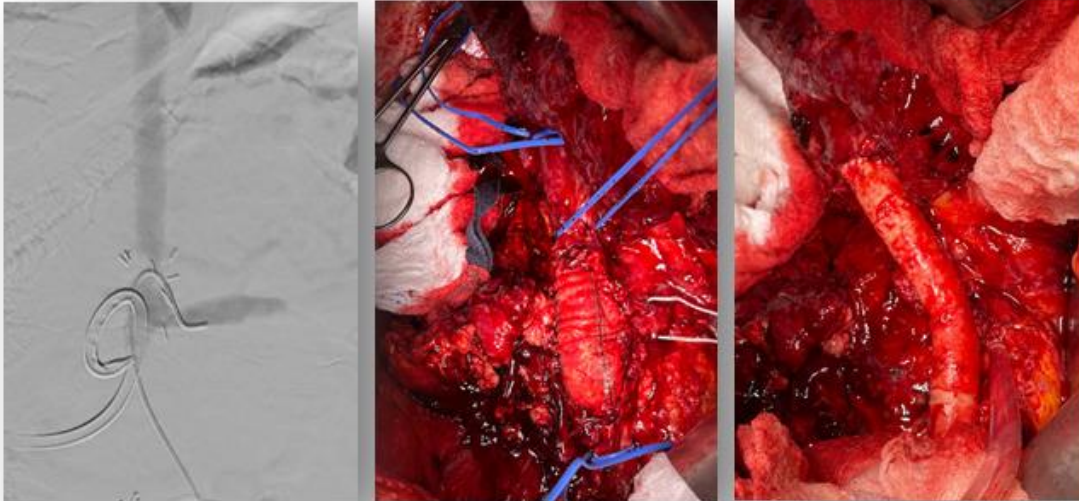


Figure 1. A.) Venogram demonstrating patent IVC and left renal vein. B.) Reconstructed IVC with prosthetic graft (takeback). C.) Reconstructed IVC with aortic homograft

References:

1. Voit A, Commander SJ, Williams Z. Partial Inferior Vena Cava Reconstruction with Cryopreserved Aortic Homograft Following Resection for Malignancy. *Vasc Endovascular Surg.* 2023 Jan;57(1):79-82.
2. Praseedom RK, Dhar P, Jamieson NV, Wallwork J, Bergman I, Lomas DJ. Leiomyosarcoma of the retrohepatic vena cava treated by excision and reconstruction with an aortic homograft: a case report and review of literature. *Surg Innov.* 2007 Dec;14(4):287-91.
3. Wachtel H, Jackson BM, Bartlett EK, Karakousis GC, Roses RE, Bavaria JE, Fraker DL. Resection of primary leiomyosarcoma of the inferior vena cava (IVC) with reconstruction: a case series and review of the literature. *J Surg Oncol.* 2015 Mar;111(3):328-33.

2:30 - 2:39 pm

TEVAR with Dissection Stent for Malperfusion in Acute Type A Aortic Dissection: A Bridge to Open Repair

Nicola Habash, BS, Avinash Saraiya, Cristina Micale, Alexander Zavitsanos, Babak Abai, MD, Dawn Salvatore, MD, Paul DiMuzio, MD, Michael Nooromid, MD
Thomas Jefferson University Hospital

Objectives

Acute Type A aortic dissection (TAAD) complicated by malperfusion syndrome (MPS) is associated with significant morbidity and mortality. Traditional open surgical repair poses significant risks and does not directly address malperfusion. However, treatment algorithms for endovascular revascularization in this patient population remain fluid and subject to ongoing debate. At our institution, we have employed thoracic endovascular aortic repair (TEVAR) as a less invasive strategy to resolve malperfusion before open intervention. This study summarizes our institutional experience with this approach.

Methods

From October 2021 to July 2024, we treated 9 cases of TAAD with MPS with TEVAR before open repair. Outcomes from TEVAR were analyzed.

Results

Patients presented with chest pain (6/8; 75%), right leg pain (5/8; 62.5%), elevated serum lactate (2.3 ± 1.4 mmol/L), and white blood cell count ($12.1 \pm 5.5 \times 10^3/\mu\text{L}$). No patients presented with rupture. Most entry tears were proximal to the innominate artery (8/9; 88.9%), with dissection extending to the abdominal aorta (4/9; 44.4%) and iliofemoral arteries (5/9; 55.6%). Five patients received two dissection stents and one stent graft, one patient received one dissection stent and one stent graft, and three patients received one dissection stent. Adjunctive visceral artery stenting was performed in four cases. There were no intraoperative complications. Technical success resolving malperfusion endovascularly was 100%. No patients required open surgery for revascularization. Two patients (2/9; 22.2%) died before the second stage of repair, from sepsis and withdrawal of care, respectively. Within 30 days of repair, renal insufficiency developed in five patients (5/9; 55.6%), with four requiring

hemodialysis (HD); HD was transient in two, while two others died while on HD (Table I). All surviving patients (7/9; 77.8%) advanced to open repair. There was no late mortality, stroke, new dissection, or device migration.

Conclusions

TEVAR for TAAD with MPS is a viable temporizing measure that can stabilize patients for potential central repair or obviate the need for further intervention. Further work is required to determine differences in endovascular treatment algorithm outcomes in TAAD with MPS.

Characteristics	% (n [‡] /N [†])
New dissection	11.1% (1/9)
Device migration	0% (0/9)
Stroke	11.1% (1/9)
SCI	11.1% (1/9)
Bowel infarct/ischemia	0% (0/9)
Renal failure/AKI	55.6% (5/9)
Did they require HD?	80% (4/5)
MI	0% (0/9)
TIA	0% (0/9)
Respiratory failure requiring oxygen	44.4% (4/9)
Additional OR trip	0% (0/9)
‡n: Number of patients or events in a specific category. †N: Total number of patients or observations in the group.	

Table I: 30-day morbidity after TEVAR

2:39 – 2:48 pm

Clinical and Financial Impact of a Machine Learning Powered Screening Program for Abdominal Aortic Aneurysms

Joseph Allen, MD, Alexander D. Pretko MS, MBA, Evan J. Ryer MD, MBA, James R. Elmore MD, Gregory G. Salzler MD, Emily Unrue DO, Anthony J. Lewis MD, David K. Vawdrey PhD, Rebecca M. Maff MS, Elliot G. Mitchell PhD
Geisinger Medical Center

Abstract

Objective

Our health system recently implemented a machine learning (ML)-enhanced abdominal aortic aneurysm (AAA) screening program to identify and screen high-risk individuals. This program, which uses clinical data to identify the top 150 high-risk patients monthly, increased the number of AAA screening ultrasound examinations and positive diagnoses. The aim of this study was to quantify the clinical and financial impacts of a ML-enhanced AAA screening program in terms of lives saved, costs incurred, payments received, and incremental cost-effectiveness ratio.

Methods

We compared 900 high-risk individuals identified from February to July 2023 (intervention cohort) with 900 individuals from February to July 2022 (comparison cohort), assessing screening rates, positive diagnoses, and outcomes using both internal electronic health record data and external research statistics for long-term estimates.

Results

This analysis demonstrated a 590% increase in AAA screening within the intervention cohort and a 238% increase in positive AAA diagnoses. The program decreased expected AAA deaths by 36%, primarily by increasing elective surgeries and decreasing emergency repairs. Financial analysis revealed an increase in costs and payments, improving hospital net income and return on investment. The incremental cost-effectiveness ratio of \$5222 per quality-adjusted life year) compares favorably with other well-accepted screening initiatives.

Conclusions

Overall, an ML-enhanced AAA screening program improves clinical outcomes and financial performance, demonstrating cost effectiveness and feasibility. Future research will refine these estimates and explore similar ML-based risk stratification programs for other conditions.

2:48 - 2:57 pm

It's Not If You Get Sued, It's When: A Survey of Trends and Perceptions of Legal Involvement Amongst Vascular Surgeons

Yun Ke (Tracy) Du, MD, Matthew J. Dougherty, MD, Keith D. Calligaro, MD, Douglas A. Troutman, DO
Pennsylvania Hospital (UPHS)

Introduction: The impact of malpractice litigation on vascular surgeons has rarely been studied, with most data remaining word-of-mouth or anecdotal. In the context of burnout in the general medical field, surveys demonstrate that involvement in malpractice litigation has deleterious impact on quality of life. Our study aims to examine the demographics of vascular surgeons involved in litigation and its effects on wellness and practice patterns.

Methods: Active SCVS (Society for Clinical Vascular Surgery) members were surveyed regarding demographics, involvement in litigation, and opinions regarding the current vascular surgery

medicolegal environment. The survey was open for two weeks, after which responses were anonymized, and data analyzed in the standard statistical fashion with significance defined as a p-value < 0.05.

Analysis: 76 (5%) total responses were received out of the 1535 active members of the SCVS. Most respondents were male surgeons (n = 63, 83%) with almost half in practice for greater than 20 years (n = 29, 46%). Respondents practiced primarily in an urban setting (n = 42, 55%), and many did not know the cost of their malpractice insurance premiums (n = 34, 44%). 72% (n = 55) of respondents reported having been named in lawsuits. Compared to peers not named in lawsuits, the group were more likely to be older than 50 (31/55 vs 3/21, p = 0.001) and have practiced for greater than 20 years (29/55 vs. 3/21, p = 0.002). Most denied feeling stigmatized by community members (69%) and half reported feeling supported by coworkers (51%) regarding their involvement in lawsuits. Surgeons reported the following directly secondary to being named in legal proceedings: burnout symptoms (n = 42, 76%), distraction from providing direct patient care (n = 51, 92%), decreased engagement in academic pursuits (n = 28, 51%), and increasing documentation and testing for defensive purposes (n = 32, 58%). Factors that did not reach statistical significance include a greater number of surgeons in urban practices being named in lawsuits (p = 0.06), perception that the prevalence of lawsuits against vascular surgeons is increasing (p = 0.23), and desire to retire due to the legal environment in vascular surgery (p = 0.19).

Conclusions: This survey of current SCVS members demonstrates that older surgeons further into their careers are more likely to have been named in lawsuits likely due to length of practice. The responses demonstrate the concerning impact of litigation on vascular surgeons' well-being, low levels of peer support, decreased ability to fully engage in direct patient care, and "defensive medicine" practices. Vascular society support regarding lawsuit involvement and young surgeons' education regarding professional liability should be emphasized. Future work will aim to increase the power of survey data by soliciting increased member participation along with analysis of other variables such geographic location and perceived practice breakdown of endovascular and open cases.

Table 1: Survey Responses Regarding Demographics and Practice Trends of Vascular Surgeons and Their Involvement in Lawsuits

	Named in lawsuit	Not Named in Lawsuit	P-value
--	------------------	----------------------	---------

Age			
50 or younger	24 (44%)	18 (86%)	
Older than 50	31 (56%)	3 (14%)	p = 0.001
Years of practice			
Greater than 20 years	29 (53%)	3 (14%)	
Less than 20 years	26 (47%)	18 (86%)	p = 0.002
Practice Setting			
Urban	34 (62%)	8 (38%)	
Non-urban (rural, suburban)	21 (38%)	13 (62%)	p = 0.06
Perception of prevalence of lawsuits filed against vascular surgeons			
Prevalence of lawsuits increasing	21 (38%)	5 (24%)	
Prevalence decreasing/No change	34 (62%)	16 (76%)	p = 0.23
Knowledge of yearly malpractice insurance			
Know malpractice insurance premium amount	33 (60%)	9 (75%)	
Don't know	22 (40%)	12 (25%)	p = 0.18
Desire to retire early due to legal environment in vascular surgery			
Yes	22 (40%)	5 (24%)	
No	33 (60%)	16 (76%)	p = 0.19
Survey answers about impact of being named in a medical malpractice case			
Supported vs. stigmatized by coworkers			
Stigmatized	3 (5%)		
Supported	28 (51%)		
Mixed/No response	24 (44%)		
Stigma from residing community			
Yes	8 (15%)		
No	38 (69%)		
Mixed/No answer	9 (16%)		
Distraction from direct patient care			
Yes	51 (93%)		
No	4 (7%)		
Distraction from academic pursuits in vascular surgery			
Yes	28 (51%)		
No	19 (35%)		
Not involved in academic pursuits	8 (14%)		
Experiencing feelings of burnout			
Yes	42 (76%)		
No	13 (24%)		
Change in clinical practice pattern			
Yes, led to more testing/charting for defensive purposes	32 (58%)		
Yes, but has not led to more testing/charting for defensive purposes	12 (22%)		
No	11 (20%)		

2:57 - 3:06 pm

Safety and Efficacy of Bivalirudin as a Heparin-Alternative in Patients Undergoing Carotid Artery Stenting

Alexandra L. Maningat, DO, Thomas A. Kania MD, Sahaj S. Shah BS, Tian Guo MS, , James R. Elmore MD, Evan J. Ryer MD, Gregory S. Salzler MD
Geisinger Medical Center

Objectives

While transfemoral carotid artery stenting and, more recently, transcarotid artery revascularization are frequently utilized to treat carotid stenosis, it is unclear how often heparin-alternatives are required for intraoperative anticoagulation and if their use affects outcomes post-operatively. The objective of this study is to compare the most commonly used heparin-alternative, bivalirudin, to heparin in the setting of these procedures.

Methods

We queried the Vascular Quality Initiative (VQI) registry for carotid artery stent procedures performed from 2010 to 2022. Univariate and one-to-one propensity matched analyses were used to compare peri-operative and long-term outcomes between patients receiving intra-procedural heparin compared to bivalirudin. The primary outcomes evaluated were postoperative neurological events, defined as stroke or transient ischemic attack (TIA), and bleeding. Secondary outcomes were rates of long-term reintervention and adverse events including myocardial infarction, 30-day, and 1-year mortality.

Results

A total of 80172 patients underwent carotid artery stenting with either heparin or bivalirudin. The mean age was 71.85 ± 9.76 years, and 50400 (62.9%) were men. 2789 (3.47%) underwent a carotid artery stenting procedure with bivalirudin. 27291 patients underwent TFCAS and 48201 underwent TCAR. Baseline characteristics and comorbidities were adjusted using propensity matched analysis to produce two cohorts containing 957 patients each. There were no significant differences in the rates

of postoperative neurological events (odds ratio [OR]: 1.44, 95% confidence interval [CI]: 0.72-2.86; $p=0.30$), bleeding (OR: 1.0; 95% CI: 0.53-1.90; $p=1.00$), 30-day mortality (OR: 2.05, 95% CI: 0.62-6.85; $p=0.24$) and 1-year mortality (OR: 1.37, 95% CI: 0.84-2.24; $p=0.21$) between the two cohorts.

Conclusion

Bivalirudin is a safe and effective alternative to heparin for patients with contraindication to heparin products who are undergoing carotid artery stenting.

3:06 - 3:15 pm

Characterizing the Demographic Composition of Editorial Board Members of High-Ranking Vascular Surgery Journals
Conor Dougherty, BS, Saaniya Farhan, BS, Cristina Micale, BS, Matthew Ruiz, BA, BS, Alya Wilkinson-Hayat, BS, Adam Ostrovsky, BS, Michael Nooromid, MD, Babak Abai, MD
Thomas Jefferson University

Objective: Editorial boards significantly shape the content of peer-reviewed academic journals.

Previous studies report a gender disparity in editorial boards across various medical specialties.

Vascular surgery is a rapidly evolving specialty, yet the demographic and academic composition of its journal editorial boards have rarely been explored. This retrospective study examined the editorial board composition of high-ranking vascular surgery journals by gender, race/ethnicity, academic position, H-index, and publication number. We secondarily compared demographic composition across American and non-American journals.

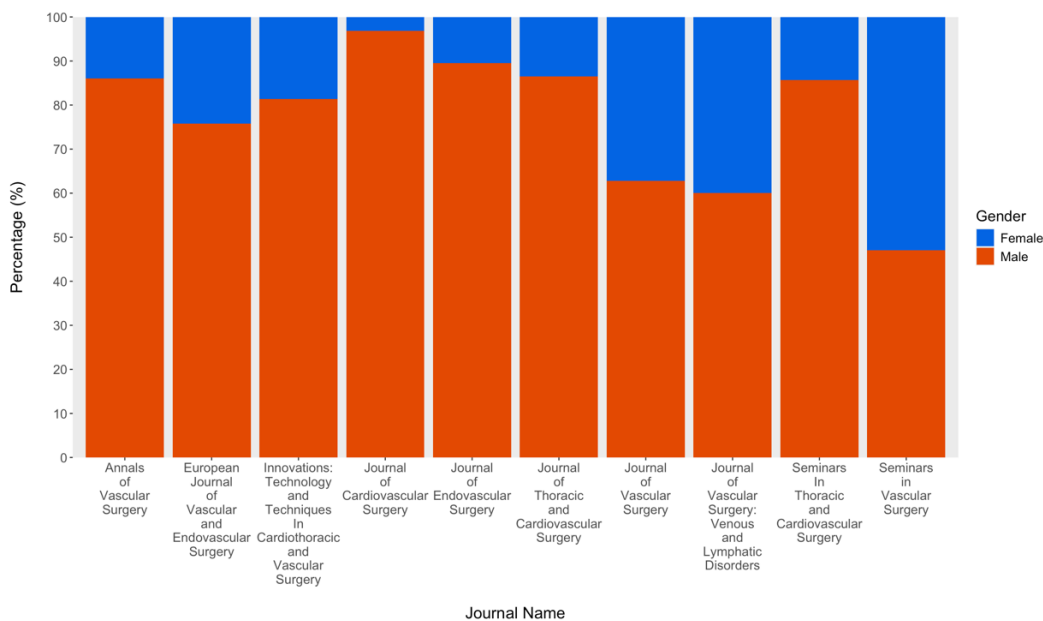
Methods: A list of 23 journals was generated from Clarivate Analytics using the search term "vascular surgery," and the 10 with the highest impact factors were selected. Editorial board member information was obtained from the journals' official websites. Only active members found on Elsevier's SCOPUS database were included, and their H-index and publication number were extracted. Gender, academic position, and race/ethnicity were extracted using university and hospital websites. Statistical analyses were performed in R Studio R 4.2.1. Fisher's exact and Kruskal-Wallis tests were used to compare between groups.

Results: 773 board members were included in the study with 84% (648/773) being male and 16% (125/773) being female. Higher proportions of male to female board members were seen across all

journals except *Seminars in Vascular Surgery* (53% female; 9/17 vs 47% male; 8/17) (Figure 1). All journals were comprised largely of Non-Hispanic White (73%; 566/773) and Asian (23%; 176/773) individuals, with Non-Hispanic Black and Hispanic members comprising only 3.8% of all boards. Relative to females, males had a significantly higher mean H-index (35 vs 23; $p < 0.001$) and publication total (205 vs 123; $p < 0.001$). The proportion of male to female editorial board members was comparable across American (386 to 80; 83% male) and non-American journals (262 to 45; 85% male) ($p = 0.4$).

Conclusions: Our findings suggest a significant disparity by gender and race/ethnicity globally within vascular surgery editorial boards. Journals should evaluate their editorial boards for adequate representation.

Figure 1: Gender Composition of Vascular Surgery Board Members by Journal.



This figure depicts the gender composition of editorial board members of high-ranking vascular surgery journals.

3:15 - 3:24 pm

Endovascular Intervention for Iatrogenic Popliteal Artery Injury Following Total Knee Arthroplasty

Tyler Fox, MD, Ioannis Tsouknidas, MD, Alvaro Mendez, MD, Alexandra Kats, MS, Henry Hirsch, MD, Robert Meisner, MD, Daniel Hayes, MD, Gerald Patton, MD, Alexander Uribe, MD, Vincent DiGiovanni, DO
Lankenau Medical Center

Objective: Popliteal artery injury is a rare but serious complication following total knee arthroplasty (TKA). These injuries have traditionally been treated with open bypass. Endovascular stenting is a promising alternative to open surgery in the recently operated knee.

Methods: The electronic medical records of four institutions were reviewed to identify patients who underwent endovascular treatment for popliteal artery injury after orthopedic knee surgery between January 2012 and August 2024. Twenty-three patients who underwent popliteal stent placement following TKA were found to be eligible for data analysis. Demographics, perioperative variables, and post-operative follow-up characteristics were recorded. The primary endpoints were primary patency, defined as no occlusion or clinically significant stenosis of the stent, and re-intervention. Institutional Review Board approval was obtained for the study.

Results: Nineteen female and four male patients, with mean age of 69.5 years, underwent endovascular stent placement for popliteal artery injury after TKA (91.3%) or revision of TKA (8.7%). Popliteal artery injury was diagnosed in the immediate post-operative period in all but one patient. The most common injuries were dissection (69.6%) followed by occlusion (39.1%). Extravasation was seen in 8.7% of cases. Stents utilized included Viabahn® (65.2%) (W.L. Gore & Associates, Inc.; Flagstaff, AZ), and Protégé™ EverFlex™ (26.1%) (ev3 Inc., Plymouth, MN). Balloon angioplasty and IVUS were utilized in 60.9% and 34.8% of cases respectively. Median follow-up was 12 months (range 1-138 months). Primary patency rates at 1, 6, 12, 24 and 36 months were 100%, 94.7%, 85.7%, 80.0%, 71.4% respectively. Four patients experienced stent occlusion or developed a clinically significant stenosis, and one patient required re-intervention.

Conclusions: Endovascular treatment with stent placement for popliteal artery injury after TKA is safe and demonstrates acceptable patency rates.

Chris DeHaven MD, Patrick D Conroy MD, Beshar Tolaymat MD, Matthew Bye MD, Katherine McMackin MD, Laurel H. Hastings MD, Bruce L Tjaden Jr. MD
Cooper University Hospital

Objectives: Major lower limb amputations, including below-knee amputation (BKA) and above-knee amputation (AKA), are critical procedures often performed on patients with severe peripheral artery disease, trauma, or uncontrolled infections. These surgeries, while often lifesaving, pose significant challenges for postoperative recovery and functional status, especially for the patient's ability to ambulate. Preoperative cardiovascular health, especially the ejection fraction (EF) measured via echocardiogram, may influence these outcomes. Ejection fraction is a common and an easy-to-obtain indicator of cardiac function, with lower values potentially indicative of heart failure or other cardiac conditions that could impact postoperative recovery and rehabilitation. This study aims to evaluate the relationship between preoperative EF and postoperative ambulation rates, as well as other clinical outcomes in patients undergoing BKA or AKA at our institution.

Methods: A retrospective review of institutional data including all major amputations performed at a tertiary care center from 2010-2020 was performed. Demographic data and patient outcomes were collected using the electronic medical record, and direct follow-up with prosthetics companies in the region. Patients with missing ejection fraction or post-operative ambulation data or who were lost to follow-up were excluded. Patients were stratified by preoperative ejection fraction as determined by echocardiogram into 5 groups (Table 1). The primary outcome was ambulation at 1 year. Univariate and multivariate regression analyses were performed using Stata 16.1 IC version.

Results: 174 patients met inclusion criteria and were stratified into 5 groups based on preoperative ejection fraction. Preoperative demographics, medical/surgical history and functional/ambulatory status were similar between cohorts, except for prior percutaneous coronary intervention (PCI), smoking status, dysrhythmia, and valvular dysfunction. Perioperative outcomes showed higher rates of prolonged intensive care unit (ICU) stay and 30-day readmission in lower EF cohorts ($p=0.002$, $p=0.003$, respectively). No significant differences were seen in complications, ambulation, functional status or need for revision. Multivariate regression analysis confirmed that postoperative ambulation was not associated with ejection fraction, but prior ipsilateral revascularization was associated with significantly higher rates of postoperative ambulation (aOR 2.61, $p=0.013$). Neither in-hospital mortality nor 1-year amputation revision was associated with preoperative ejection fraction.

Conclusions: Preoperative ejection fraction was not associated with higher rates of complications, postoperative ambulatory status or functional status, need for amputation revision to a higher level, or overall survival. This was confirmed on logistic regression. Patients who had undergone prior ipsilateral revascularization had a greater likelihood of ambulation after major amputation. This study suggests preoperative ejection fraction does not influence the outcomes of major amputations.

Table 1: Perioperative and Long-term outcomes after major amputation, stratified by ejection fraction cohorts.

Variables	EF >60% N= 55	EF 45-59% N=78	EF 30-44% N=21	EF 21-29% N=16	EF <=20% N=4	P value
Outcomes						
Length of Stay (days) Mean (SD)	11.5 (6.4)	16.2 (13.9)	13.7 (7.3)	15.3 (15.8)	23.5 (10.6)	0.091
ICU Stay (days) Mean (SD)	0.3 (1.0)	1.0 (4.2)	0.2 (0.5)	1.6 (4.0)	7.2 (9.1)	0.002
Discharge Location						
Home	7 (13%)	12 (15%)	4 (19%)	4 (25%)	0 (0%)	0.66
Subacute Rehabilitation	30 (55%)	31 (40%)	11 (52%)	7 (44%)	2 (50%)	
Acute Rehabilitation	18 (33%)	35 (45%)	6 (29%)	5 (31%)	2 (50%)	
In Hospital Complications						
None	53 (96%)	69 (88%)	21 (100%)	16 (100%)	4 (100%)	0.79
Bleeding	1 (2%)	2 (3%)	0 (0%)	0 (0%)	0 (0%)	
Infection	1 (2%)	4 (5%)	0 (0%)	0 (0%)	0 (0%)	
Reoperation	0 (0%)	3 (4%)	0 (0%)	0 (0%)	0 (0%)	
30-Day Readmission	9 (16%)	24 (31%)	8 (38%)	3 (19%)	4 (100%)	0.003
Ambulation at 1 Year						
Yes	28 (51%)	48 (62%)	10 (48%)	7 (44%)	4 (100%)	0.18
No						
Days to Ambulation (Mean(SD))	429.8 (560.6)	291.4 (221.9)	401.5 (185.9)	427.3 (456.5)	225.8 (91.5)	0.50
1 Year Functional Status						
Independent	16 (36%)	12 (22%)	2 (15%)	3 (23%)	1 (50%)	0.70
Partially Dependent	14 (32%)	26 (47%)	6 (46%)	6 (46%)	1 (50%)	
Dependent	14 (32%)	17 (31%)	5 (38%)	4 (31%)	0 (0%)	
1 Year- Higher Level Amputation Revision	5 (9%)	10 (13%)	3 (14%)	2 (12%)	1 (25%)	0.87
Time to Higher Level Revision (days)	94.6 (80.4)	92.4 (110.9)	82.5 (26.2)	304.5 (408.0)	25.0 (.)	0.39
Time to Most Recent Follow Up	886.7 (951.2)	917.4 (854.0)	807.0 (754.1)	770.6 (836.9)	1726.2 (1086.9)	0.39
30-Day Mortality	0 (0%)	0 (0%)	0 (0%)	0 (0%)	(0%)	1.00
1-Year Mortality	5 (9.1%)	5 (6.4%)	2 (9.5%)	1 (6.3%)	0 (0%)	0.092
Overall Survival	16 (29%)	17 (22%)	3 (14%)	3 (19%)	2 (50%)	0.44

Lower Extremity Bypass Surgery for Severe Peripheral Arterial Disease

Fadi Samaan, BS, Elizabeth Lavanga, BS, Leana Dogbe, BS, Ahsan Zil-E-Ali, MBBS, MPH, Faisal Aziz, MD, MBA, FACS, DFSVS
Penn State Health Milton S. Hershey Medical Center


Objective. This study aimed to assess the association of preoperative gabapentinoids (GBP) use with the postoperative length of stay for patients undergoing peripheral arterial lower extremity bypass surgery (LEB) for lifestyle limiting claudication and chronic limb threatening ischemia (CLTI) at a tertiary care hospital.

Methods. Patients undergoing lower extremity bypass surgery during the period between 2010 to 2020 at Penn State Health Milton S. Hershey Medical Center were stratified into two groups based on the preoperative use of prescribed gabapentinoids (GBPs vs No GBPs). Patients' preoperative characteristics, comorbidities and medications were assessed, and the outcomes of interest were analyzed in univariate analysis, stratified analysis and by multivariable regression models. Primary outcomes were 30-day mortality and length of stay

Results. The study cohort comprised 359 patients. The GBPs group comprised 125 patients with a mean (SD) age of 61.6 (\pm 10.2) years and the No GBPs group consisted of 234 patients with a mean (SD) age of 64.6 (\pm 12.2) years. In terms of outcomes, the patients in the GBPs group were more likely to have longer postoperative length of stay (LOS; 9.3 ± 11.1 vs. 6.4 ± 5.0 days No GBPs, $p=0.008$). In multivariable analysis, the patients in the GBPs group had 92% (AOR 1.92 [1.16, 3.18], $p=0.01$) increase in the odds of having a LOS above 6-day calculated-median in comparison to the No GBPs group.

Conclusion: This retrospective analysis of patients undergoing LEB at a tertiary care hospital shows a significant association between preoperative gabapentinoids use and the longer postoperative length of stay.

Figure 1: Multivariable adjusted analyses assessing the odds of having above 6-day calculated-median length of stay with preoperative use of gabapentinoids



Point estimate (AOR) plotted as red diamonds and 95% confidence interval plotted as black error lines. Model 1 (statistically significant variables) adjusted for age, preoperative glucose, indication, Insulin Dependent Diabetes Mellitus (IDDM), functional status, tissue loss, graft type, and bypass type. Model 2 (clinically significant variables) adjusted for age, gender, history of CHF, MI, CVA with deficit, IDDM, non-IDDM, preoperative glucose, smoking, alcohol use, functional status, tissue loss, graft type and bypass type.

3:42 – 3:51 pm

The Paradox of Early Surgery and Worse Outcomes in Ruptured Abdominal Aortic Aneurysms

Ahsan Zil-E-Ali, MBBS, MPH, Aditya Safaya, MD, Esther S. Choi, MD, Kristine So, MD, Faisal Aziz, MD
Penn State Health Milton S. Hershey Medical Center

Objectives

Time from symptoms to surgery is a critical factor in surgical care. This study evaluates the impact of symptom-to-incision time on postoperative outcomes in patients undergoing open repair for ruptured abdominal aortic aneurysms (rAAA).

Methods

The Society for Vascular Surgery Vascular Quality Initiative (SVS-VQI) registry was studied from 2003 to 2021. Patients undergoing open repair for rAAA were divided into two groups based on the median split of symptom-to-incision time of 7 hours (Group I < 7 hours) and Group II (≥7 hours). Outcomes were compared between groups, and multivariable logistic regression was used to assess 30-day mortality and RTOR, adjusting for various characteristics.

Results

A total of 2,942 patients were selected for analysis of in which Group I comprised of 1,259 patients, and Group II with 1,512 patients. Group I had significantly higher rates of in-hospital mortality compared to Group II (44.09% [n=555] vs. 39.88% [n=603], p=0.018) and higher RTOR rates (37.81% [n=476] vs. 29.03% [n=439], p< 0.001). Rates of dysrhythmia were similar between the groups (23.52% [n=296] vs. 22.92% [n=346], p=0.710), as were rates of congestive heart failure (8.47% [n=107] vs. 7.74% [n=117], p=0.481). Postoperative myocardial infarction rates showed no significant differences: non-STEMI occurred in 7.17% [n=90] of Group I and 6.77% [n=102] of Group II, while STEMI occurred in 8.21% [n=103] of Group I and 7.84% [n=118] of Group II (p=0.851). Group II had higher rates of respiratory complications (8.94% [n=135] vs. 7.59% [n=96], p=0.021) and renal complications (25.02% [n=378] vs. 24.31% [n=306], p=0.045). Stroke incidence was 1.25% across both groups, with ischemic stroke occurring slightly more frequently in Group II (1.38% [n=21] vs. 1.08% [n=14]), while hemorrhagic stroke occurred more frequently in Group I (2.24% [n=28] vs. 1.97% [n=30], p=0.708).

Multivariable analysis showed that Group II had lower odds of 30-day mortality (adjusted odds ratio [aOR] 0.66, 95% CI 0.54-0.86, $p < 0.05$) and lower odds of RTOR (aOR 0.61, 95% CI 0.54-0.78, $p < 0.05$) compared to Group I.

Conclusions

Patients presenting within 7 hours (Group I) had higher mortality and RTOR rates, likely reflecting more severe hemodynamic instability at presentation. In contrast, those presenting after 7 hours (Group II) had better outcomes despite longer symptom-to-incision times, possibly due to slower leaks or contained ruptures allowing for preoperative stabilization. These findings highlight that patient physiology, rather than time alone, is a key determinant of outcomes in ruptured AAA repair.

3:51 – 4:00 pm

Female Sexual Dysfunction After EVAR

Alec Schubert MD, Bruce L Tjaden Jr MD, Patrick D. Conroy MD, Olivia M. Toner BS, Holly A. Seybold BA, Alison M. Blumstein BS, Benjamin Feng, BS, Philip Batista MD, Laurel H. Hastings MD, Joseph V. Lombardi MD, MBA, Katherine McMackin MD
Cooper University Hospital

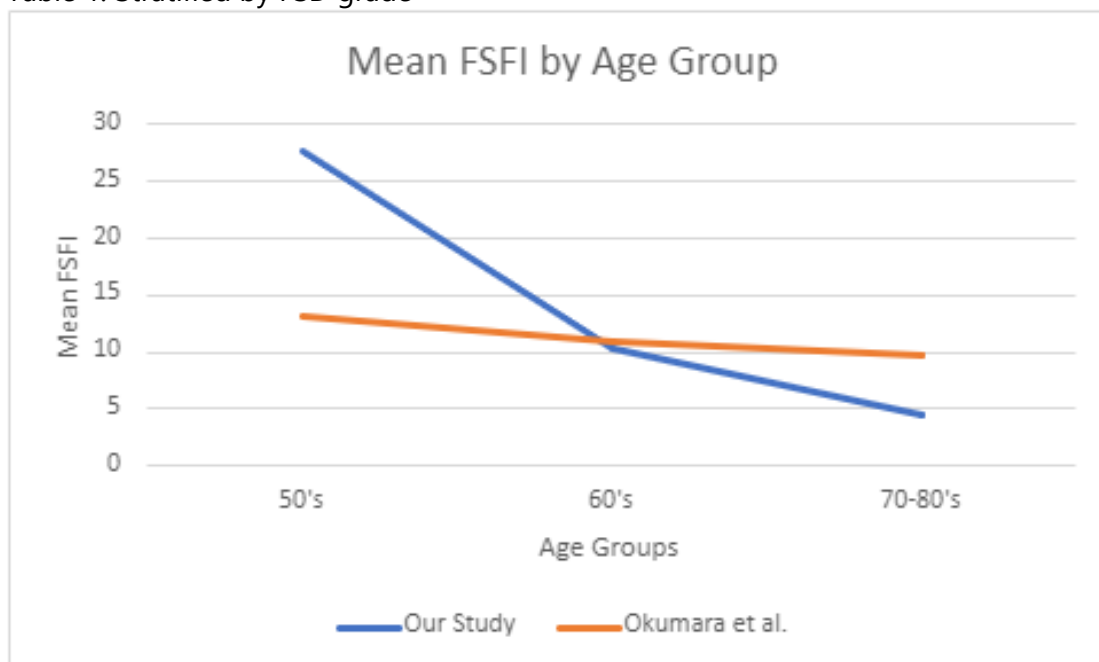
To date, no literature seeks to evaluate sexual dysfunction amongst female patients. The female sexual function index survey (FSFI) is a validated tool to assess sexual dysfunction. In this study, we aim to evaluate female sexual function after EVAR, while also promoting advocacy and collaboration for larger-scale multi-center efforts related to this topic. A single-center retrospective study was performed to identify females undergoing EVAR between 2014-2024. All living females who had undergone EVAR were contacted via phone and asked to complete the FSFI. Simple linear regression analysis was used to evaluate the relationship between age and sexual dysfunction. The data was then compared to previously published FSFI scores in patients of various ages who had not undergone vascular surgery. Furthermore, a chi-square test was used to determine the significance of outcome variables in table 1. A total of 179 female patients underwent EVAR during the study period. 42 were excluded due to mortality. 55 patients were successfully contacted. Of those successfully contacted, 34 (62%) declined to participate. A total of 16 patients returned completed surveys. None of the patients had hypogastric exclusion during their case. Stratification of female sexual dysfunction (no FSD, mild, severe) based upon FSFI scoring yielded statistically significant differences for age and mean FSFI score. Further sub-categorical analysis of desire, arousal, lubrication, orgasm, and satisfaction displayed statistically significant differences as well (table 1). When comparing our mean

FSFI scores by age grouping to the data presented in Okumara et al., our patients scored 5.4 points lower (a mean score of 4.4 from our data compared to a mean of 9.8 seen in their study) (figure 1). While age can be a predictor and contributor to FSD, our data provides potential evidence that EVAR even without hypogastric artery coverage may also worsen FSD, especially for populations over 70 years of age. We recognize the limitations of current data in terms of number of participants, but would suggest that further collaboration and expansion to a multi-center study may better characterize how this common procedure may alter female sexual function.

Tables and Figures:

Factor	No FSD	Mild	Severe	p-value
N	1	2	13	
Age , mean (SD)	55 (.)	61.5 (6.3639612)	74.846153 (6.6061354)	0.008
FSFI, mean (SD)	33.6 (.)	23.45 (2.6162951)	4.6461538 (1.0397238)	<0.001
desire, mean (SD)	3.6 (.)	4.5 (1.2727922)	1.8461538 (1.0524696)	0.013
arousal, mean (SD)	6 (.)	2.85 (.21213203)	0 (0)	<0.001
lubrication, mean (SD)	6 (.)	.9 (1.2727922)	0 (0)	<0.001
orgasm, mean (SD)	6 (.)	3.8 (2.5455844)	0 (0)	<0.001
satisfaction, mean (SD)	6 (.)	5.4 (.28284271)	2.8 (.8326664)	<0.001
pain, mean (SD)	6 (.)	6 (0)	0 (0)	
hx_sex dysfn	0 (0%)	0 (0%)	2 (15%)	0.77

Table 1: Stratified by FSD grade



4:00 – 4:09 pm

Clinical Outcomes of Femoral Endarterectomy using Monitored Anesthesia Care

Brian N. Lifschutz, DO, Osama Anis, MD, James Zamora, MD, Hudson Carter, MD, Robert Myers, MD, Jaclyn Milici, MD, and Danielle M. Pineda, MD
Jefferson-Abington Hospital

Femoral endarterectomy aims to restore lower extremity perfusion and alleviate the symptoms of peripheral arterial disease caused by common femoral artery atherosclerotic plaque. The choice of anesthesia used in this procedure is critical, as it influences peri-operative outcomes, patient satisfaction, hospital length of stay, and recovery times. The traditional choice is general anesthesia due to its allowance for paralysis and adequate analgesia. Recent trends and emerging evidence suggest that monitored anesthesia care (MAC) and locoregional anesthesia techniques may offer significant advantages over general anesthesia (GA), including a decreased incidence of peri-operative and anesthesia-related complications, shorter hospital length of stay, and faster recovery times. The use of MAC is commonly employed as an effective alternative to GA in lower extremity revascularization procedures, especially in those patients with co-morbidities that contraindicate the use of GA. To date, there is a paucity of evidence supporting the use of MAC specifically for femoral endarterectomy. In this retrospective case-control study, we evaluate the clinical outcomes of 72 patients undergoing femoral endarterectomy, comparing those who received GA and those who received MAC. We examine peri-operative morbidity, procedure duration, in-hospital length of stay, requirement for intensive level of care, and post-operative narcotic use. Our preliminary analysis reports five patients who have undergone femoral endarterectomy under MAC. Of these, there were no complications, length of stay was one day, and patients tolerated their procedures well. This analysis aims to provide the needed evidence to inform clinical practice in the setting of femoral endarterectomy, potentially leading to a paradigm shift in anesthesia modality choice for these common procedures.

Smaller and More Rural Hospitals have Worse Outcomes in Aortic Dissection Management

Patrick D. Conroy MD, Bruce Tjaden MD, Beshar Tolaymat MD, Alec Schubert MD, Laurel Hastings MD, Katherine McMackin MD, Philip Batista MD, Joseph V Lombardi MD
Cooper University Hospital

Objectives: We examined hospitalizations, intervention approaches, and hospital characteristics for Aortic Dissection over time.

Methods: We identified all patients presenting with aortic dissection, both ascending and descending, (ICD-9-CM: 441.0; ICD-10-CM: I71.0) in the NIS between 2000-2021. We then examined the utilization of open repair, endovascular and complex-endovascular repair, as well as nonoperative/medical management. Stratified by hospital setting (urban-teaching, urban-nonteaching, and rural), we analyzed trends of interventions and in-hospital mortality over time. If an operation was performed, we were able to discern between ascending/arch or descending aorta after the 2017 ICD revision. We used Cochran–Armitage z statistic tests for a linear trend to generate trend p-values and performed linear regression analyses using Stata 17.0.

Results: 553,030 patients with aortic dissection were identified. The number of inpatients in the US with aortic dissections has increased, with an incidence of 26.7 cases/100k in 2000 to 47.2 cases/100k in 2020 ($p < 0.01$). Overall, including all hospital settings, aortic dissections were less frequently managed nonoperatively (2000-2021: 83%-71%) and more frequently managed endovascularly (Figure), with 85% of all descending and 16% of all ascending/arch aortic dissections undergoing TEVAR in 2021. Over time, aortic dissections have increasingly been managed at urban-teaching hospitals (2000-2021: 72%-92%; $p < 0.01$). Since 2016, urban-teaching hospitals more frequently intervened on aortic dissections compared to their rural counterparts (21% vs. 6%; $p < 0.01$), despite having similar rates of failed medical management (9.8% vs. 8.2%; $p = 0.30$). Finally, comparing the last 5-years, urban-teaching hospitals have lower mortality rates when managing aortic dissection versus their rural counterparts (10.9% vs 11.7%, $OR = 1.10$; $p = 0.02$) and if managed operatively, there was a lower associated risk of mortality at urban-teaching hospitals compared to urban-nonteaching hospitals (12.5% vs. 17.3%, $OR = 1.46$; $p < 0.01$).

Conclusion: Both aortic dissection hospitalizations and interventions have significantly increased over the past two decades in the US. The growth of large hospital systems and their absorption of smaller hospitals into integrated primary through quaternary care centers has resulted in an increase in “regionalization” of care, in which complex cases are transferred to larger urban teaching centers. Our analysis suggests there is a mortality benefit from the centralization of aortic care to tertiary/urban-teaching centers, though further research into this question is required.

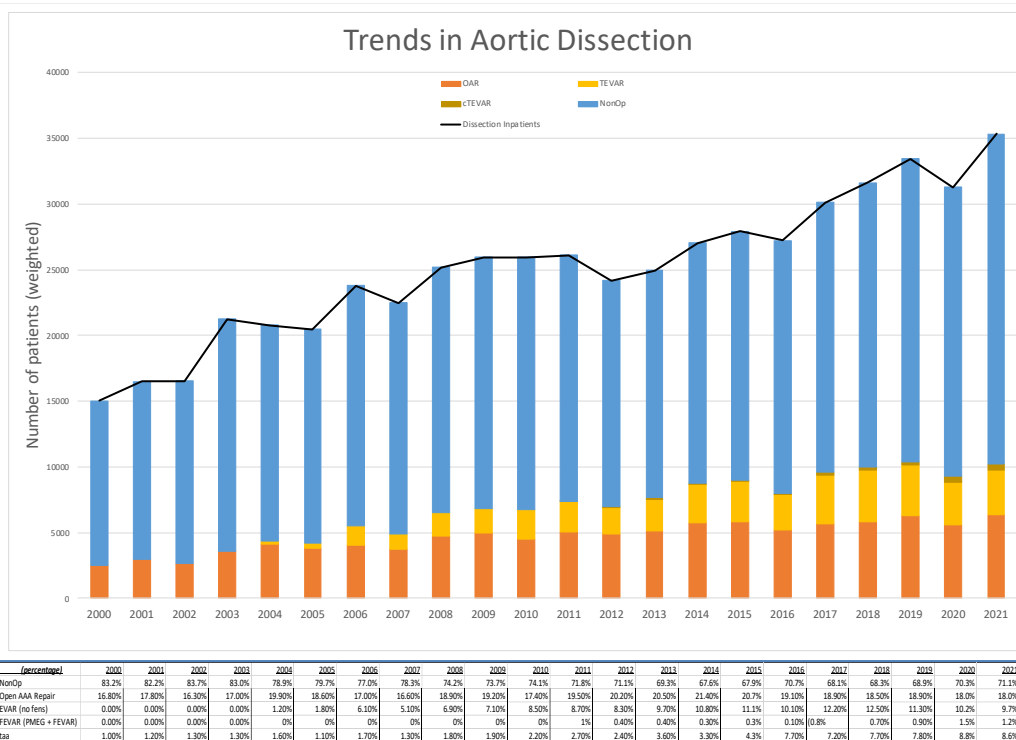


Figure 1: Overall trends in aortic dissection management.

4:18 – 4:27 pm

Novel Morphological Predictors of Stroke Risk in Carotid Artery Stenosis: A Comparative Analysis of Plaque Characteristics Beyond Luminal Narrowing

Danielle C. Brown, BS, Patrick D. Conroy MD, Bruce L Tjaden Jr MD, Katherine McMackin MD, Laurel H. Hastings MD, Philip M Batista MD, Joseph L. Lombardi MD MBA
Cooper University Hospital

Objectives: Carotid artery stenosis is a critical risk factor for ischemic stroke. Traditionally the degree of luminal narrowing has been the primary focus for assessing stroke risk, but recent studies indicate that other plaque features may significantly influence plaque stability and cerebrovascular events. We seek to enhance stroke-risk stratification and enhance patient selection using novel morphological characteristics of carotid artery plaques seen on computed tomography angiography.

Methods: Our retrospective single-institution cohort analysis included 94 patients (42 symptomatic; 52 asymptomatic) from 2020-2023 who underwent Transcarotid artery revascularization or Carotid endarterectomy. The lesion characteristics analyzed were lesion length and circumference, maximum occlusion-percentage, minimum ICA flow-diameter, maximum lesion-protrusion, and distance between start of the lesion and carotid bifurcation. Student’s T-test and Logistic regression were used to analyze stroke risk.

Results: There was no significant difference in the percent occlusion of the internal carotid artery ($p=0.45$), lesion length ($p=0.21$), or max lesion protrusion ($p=0.21$) between the symptomatic and asymptomatic cohorts ($p=0.45$). More circumferential lesions were associated with asymptomatic plaques ($OR=0.17, p=0.03$), as well as lesions that started further from the bifurcation ($OR=0.94, p=0.05$) and internal carotid arteries that had larger flow diameters despite their large lesions ($OR=1.62, p=0.02$). Our model, incorporating minimum flow diameter, lesion circumference, and the lesion-start-to-bifurcation length, had an area under the ROC curve (AUC) of 0.761 while a model utilizing only percent occlusion yielded an AUC of 0.55.

Conclusion: We describe several novel variables that may confer predictability of the stroke risk of carotid artery plaques, with our 3-variable model having a superior predictive capability compared to percent occlusion alone.

Table 1: Various novel morphology variables and their Predicting Abilities (Odds Ratios) for Stroke in Carotid Artery Stenosis (Continuous Independent Variables : Binary Dependent)

<i>Variables</i>	<i>t-test mean difference</i>	<i>p-value</i>	<i>OR</i>	<i>p-value</i>	<i>aOR[^]</i>	<i>p-value</i>
Lesion Length	3.1 mm	0.21	0.975	0.22	0.980	0.43
Lesion Circumference	13%	0.02*	0.175	0.03*	0.054	0.02*
Distance Start-of-plaque : Bifur	4.6 mm	0.03*	0.936	0.06	0.913	0.12
Minimum ICA Flow Diameter	0.6mm	0.01*	1.622	0.02*	1.561	0.11
Percent Occlusion	0.02%	0.45	0.224	0.449	1.105	0.97
Max Protrusion	0.5mm	0.21	1.166	0.21	1.346	0.12

* = statistically significant

[^] = adjusted for: Sex, Race, HTN, CAD, CHF, DM, Smoking, Preop Meds (ACEi, Plavix, ASA, B-blocker, Statin)

4:27 – 4:36 pm

Transcarotid Artery Revascularization is Safe and Durable in Patients with Hostile Neck Anatomy

Ryan Lee, BS, Michael Qaqish, MD, Sharvil Sheth, MD
St. Luke's University

Introduction

Transcarotid artery revascularization (TCAR) has emerged as a promising treatment for carotid artery stenosis (CAS). Prior neck irradiation or surgery is thought to be associated with more difficult neck surgery due to the presence of fibrosis and altered neck anatomy (hostile neck). Studies investigating the safety and efficacy of TCAR in these patients are limited. This study aims to compare short- and long-term outcomes of patients with and without hostile neck anatomy who underwent TCAR.

Methods:

Retrospective chart review was performed for all consecutive patients who underwent TCAR from August 2016 to December 2023 at our institution. Patient demographics, procedure characteristics, and outcomes were collected for each patient up to November 30, 2024. The primary outcome was freedom from restenosis/reintervention and long-term rates of ipsilateral stroke following TCAR. Secondary outcomes were differences in procedure characteristics between TCAR with and without hostile neck. Kaplan-Meier survival curves were constructed to assess freedom from restenosis/reintervention using log-rank tests.

Results:

During the study period, 320 patients underwent TCAR. Of the 64 patients who had hostile neck, 45 patients had prior neck surgery, and 22 patients had prior neck irradiation. 256 patients who underwent TCAR did not have hostile neck anatomy. Patients with hostile neck were less likely to undergo TCAR for symptomatic CAS (34.375% vs. 48.04%, p = 0.0488). Flow reversal time was increased in patients with hostile neck anatomy (14.35 vs. 12.56 minutes, p = 0.0485), but other procedural characteristics (fluoroscopy time, procedure time, lesion length) were not significantly different. There was no difference in ipsilateral stroke outcomes at 30 days, 1 year, or 5 years. There was no difference in long-term stroke-free survival at the end of the study period (p = 0.829), even after stratifying for neck irradiation and neck surgery. Neck irradiation alone was associated with increased risk of restenosis/occlusion (18.2% vs. 5.9%, p = 0.0278). Freedom from stent restenosis/reintervention is shown in Figure 1.

Conclusion:

TCAR is a safe procedure for patients with prior neck surgery or irradiation for the treatment of CAS. Prior neck irradiation was associated with increased risk of stent restenosis or reintervention but was not associated with higher risk of stroke. Flow reversal times were longer for patients with hostile neck, but otherwise procedural characteristics were not significantly different between patients with and without hostile neck. Patients with and without hostile neck had comparable short-term and long-term outcomes following TCAR.

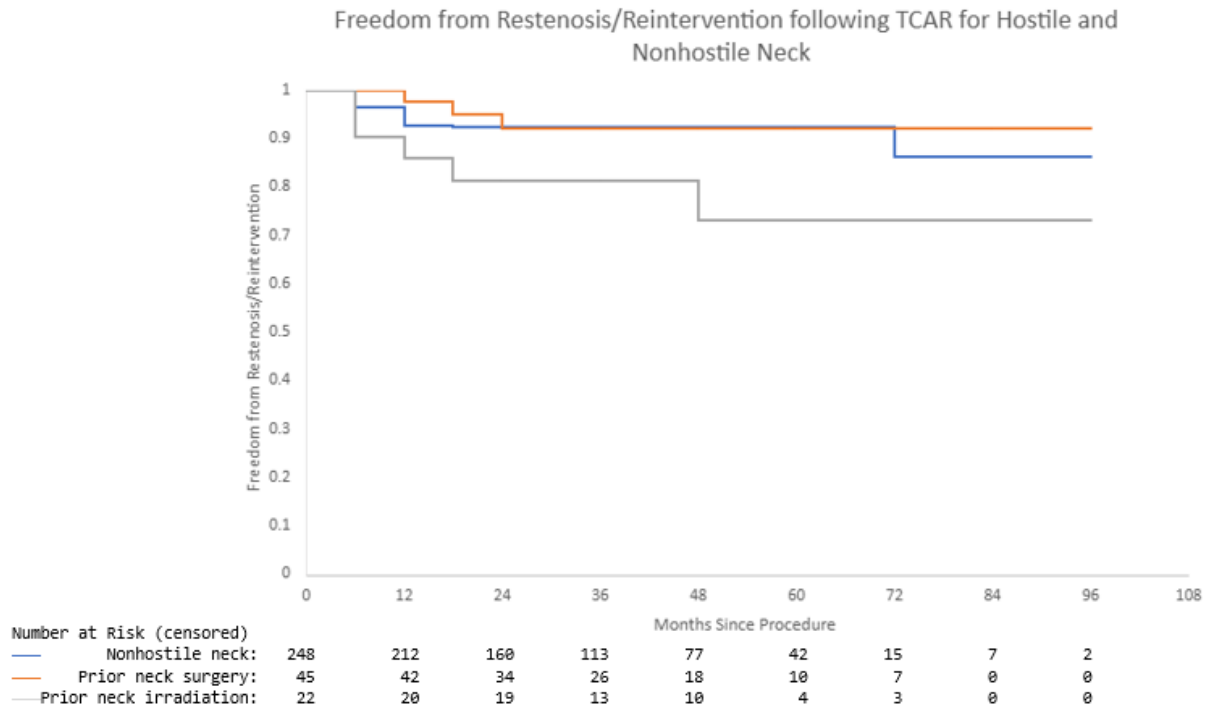


Figure 1. TCAR for treatment of CAS in patients with prior neck irradiation is associated with decreased long-term freedom from restenosis/reintervention compared to patients with nonhostile neck (log-rank p-value = 0.0335). There was no significant difference in long-term freedom from restenosis/reintervention between patients with prior neck surgery and nonhostile neck (log-rank p-value = 0.747).